

Initial Experience with Surgical Telementoring in Pediatric Laparoscopic Surgery Using Remote Presence Technology

Steven S. Rothenberg, MD, Suzanne Yoder, MD, Saundra Kay, MD, and Todd Ponsky, MD

Abstract

Purpose: To evaluate the efficacy of remote presence technology in surgical mentoring.

Methods: A self-propelled robot, which is controlled from a wireless remote control station (Laptop computer) and provides two-way audio and visual communication, was used to allow an experienced endoscopic surgeon to provide mentoring during three unique laparoscopic cases. This first was a laparoscopic exploration in a 9-month-old child with clinical evidence of intermittent obstruction but nondiagnostic imaging studies. The second was a 4-day-old, 3-kg infant with a congenital diaphragmatic hernia, and the third was a 1-day-old child with duodenal atresia. The robot was used to visualize the patient and radiologic studies, telestrate suggestions for trocar placement, visualize the laparoscopic procedure, and provide advice during the procedure. In the second case, another surgeon at a remote site control station watched the surgery and asked questions.

Results: The procedures were completed successfully in 90, 30, and 90 minutes. The first case included identification of the obstructing lesion (internal jejunal polyp) and intestinal resection and anastomosis. The second case involved resection of the hernia sac and repair of the congenital diaphragmatic hernia. The third consisted of identification of the site of atresia and identification of the site for the proximal and distal enterotomy. The robot allowed excellent visualization of the procedures and direct communication between the surgeon and mentor was uninterrupted throughout the case. Both surgeon and mentor felt the telementoring assisted in the case.

Conclusions: While this is a limited series, the initial evaluation of this remote presence technology in the operating room suggests that it may be extremely usefully in adding surgical experience and expertise in minimally invasive surgery.

Introduction

WITH EVER INCREASING INNOVATION and technological advancement, physicians and especially surgeons are forced to learn and adapt to an ever changing array of instruments and techniques. This has been especially true in the field of minimally invasive surgery. Not only must the surgeon learn how to use new equipment, but he or she also has had to develop a whole new skill set to effectively use these tools. The surgeon has been forced to learn to work in a two-dimensional visual environment, must adapt how a case is set up and approached, and must recognize different visual clues and landmarks to accomplish the same procedure previously done via an open laparotomy. It has clearly been shown in previous studies that there is a fairly steep learning curve for advanced minimally invasive surgical (MIS) procedures¹ and that surgical mentoring can help diminish this curve.² However, that ability to have an onsite

mentor for advanced laparoscopic procedures may not always be possible or practical, especially in a field such as pediatric surgery where there are a limited number of experienced mentors, certain case are extremely rare and may only occur a few times a year, many of these are semi-emergent, and it may not be feasible or cost-effective to delay the case until an experience mentor is present. To address some of these issues, we used a self-propelled robot in the operating room controlled by a experienced mentor at a remote site to see if there was a perceived benefit by both the surgeon and the mentor.

Methods

A self-propelled robot, the RP-7 (Intouch Health, Santa Barbara, CA), which is controlled from a wireless remote control station (laptop computer) and provides two-way audio and visual communication, was used to allow an expe-

rienced laparoscopic pediatric surgeon to provide mentoring during three unique laparoscopic cases. The robot, which is 65 inches tall and has a base approximately 2.5 ft², is controlled by a joystick connected to the laptop. It can be run by the laptop anywhere in the world a broadband signal can be obtained. The mentoring surgeon can drive the robot in the operating suite, visualize the operative field as well as the flat panel monitors in the MIS suite, communicate in real time verbally with the surgical team, and send telestrations, which appear on the robot's flat panel screen. This allows the mentor to help with trocar placement, structure identification, and operative setup. Three different cases were performed by two different surgeons with the same surgical mentor at different remote sites. The first case was a laparoscopic exploration in a 9-month-old child with clinical evidence of intermittent obstruction but nondiagnostic imaging studies. The second was a 4-day-old, 3-kg infant with a congenital diaphragmatic hernia (CDH), and the third was a 1-day-old child with duodenal atresia. The robot was used to visualize the patient and radiologic studies (Fig. 1), telestrate suggestions for trocar placement (Fig. 2), visualize the laparoscopic procedure, and provide advice during the procedure. In the second case, another surgeon at a second remote site control station watched the surgery and asked questions.

Results

All three procedures were completed successfully laparoscopically in 90, 30, and 90 minutes, respectively. The first case included identification of the obstructing lesion (internal polyp) and intestinal resection and anastomosis. The second case, a Morgagni CDH, involved resection of the hernia sac and repair of the defect. The third case required identification of the site of atresia as well as the sites and orientation for the proximal and distal enterotomies for the duo-

denoduodenostomy. The robot allowed for excellent visualization of the procedures both on the operative field and on the camera monitor. It also allowed direct communication between the surgeon and mentor, which was uninterrupted throughout the case. Interaction between the telementor and surgeon included review of the pertinent X-rays and discussion of the presumed pathology, site selection for trocar placement, identification of the surgical lesion, and in the case of the duodenal atresia, an extensive discussion with schematic drawings of where to make the enterotomies and how to construct the anastomosis. While no specific score scale was used, both the surgeon and mentor felt the telementoring assisted in the case. The greatest benefits were felt to be in the initial setup (trocar placement), identification of abnormal anatomy, and approach to the needed repair. Both the surgeon and the mentor also felt that a significant time savings was achieved during the case because of the guidance of the experienced mentor.

Discussion

The rapid evolution of emerging surgical technologies and procedures has necessitated that surgeons rapidly assimilate and train in a varying array of new procedures. This has been especially evident in the field of MIS. A large numbers of hands-on courses, teaching aids, video files, and mentoring programs have been developed to help surgeons learn and assimilate these techniques.³ However, there is a well-recognized disconnect between a surgeon taking a training course or a mini-fellowship and successfully applying these techniques in their practice. Having an on-site mentor to help bridge this training gap is an effective technique but is often not logistically or economically feasible. This is especially true in a highly specialized field where there are few expert mentors, or the frequency of a specific case is rare. It is also

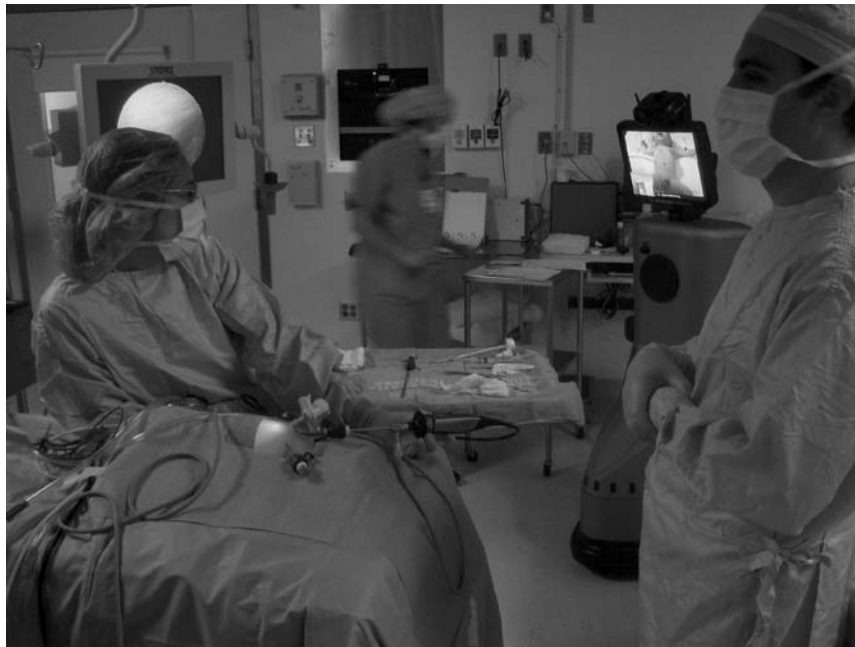

FIG. 1. The RP-7 present in the operating room during a laparoscopy on a neonate with duodenal atresia. The robot is positioned to allow visualization of the patient and the camera monitors.

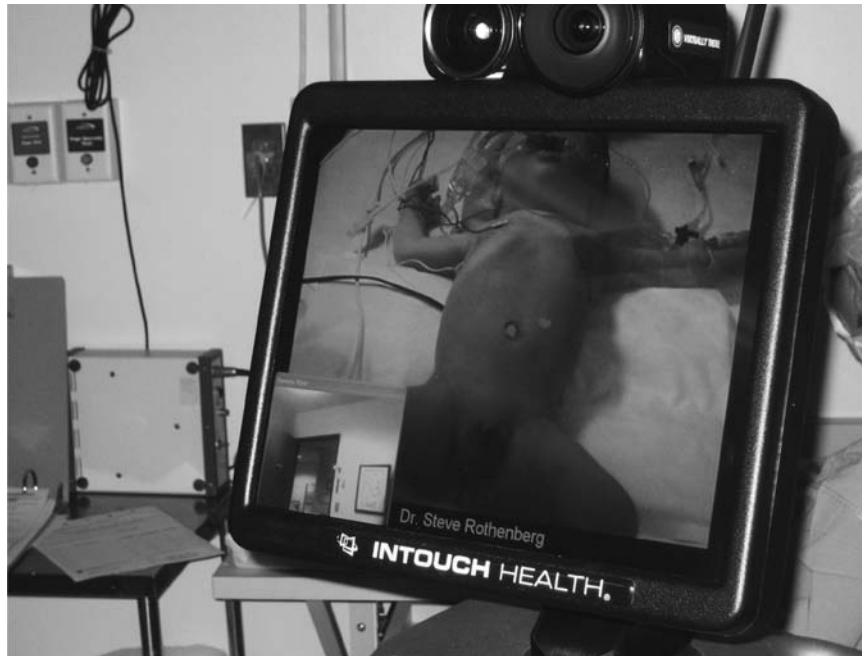

FIG. 2. Recommended trocar placement is demonstrated by the mentor on the robot's flat panel monitor. The picture is captured by the robot's camera, modified by the surgical mentor, and transmitted back to the operating room.

very difficult to arrange if the cases are of an emergent or semiemergent nature, such that time restraints do not allow a mentor to be on site.

Recognizing the needs and limitations of on-site mentoring has led to the exploration for a more reliable and economic solution. The wide use of the Internet and the ability to transfer images and audio communication instantaneously seemed a logical and cost-effective solution, and the RP-7 mobile robot had already proved itself in telemedical endeavors where a physician for various reasons could not be on site.⁴

RP-7 has been used extensively to allow physicians to monitor patients within the hospital from remote locations as close as the physician's office across the street to other hospitals within the city or region, and even transcontinentally. The efficacy of this technology in rounding on and managing patients and providing off-site consultative services has been well documented. With this in mind, it seemed a logical extension to bring the robot into the operating room environment to determine if similar consultation and mentoring could be achieved.

In these cases, the surgical mentor was off site. In two cases, the mentor was in the same city, and in one case, the

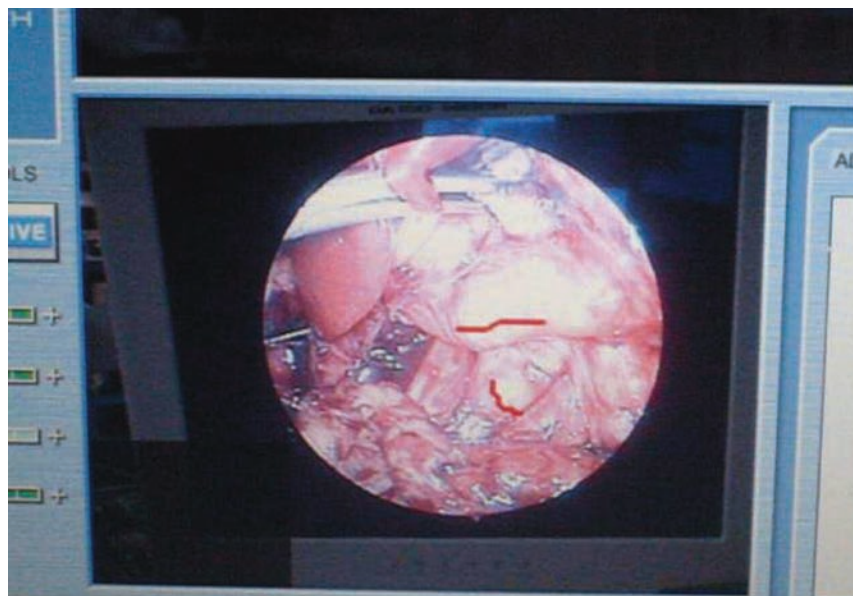


FIG. 3. Telestration is used to show the recommended site of the enterotomies in a case of duodenal atresia.

mentor was 1500 miles away. In all cases the communication between the surgeon and mentor flowed well enough to facilitate the procedure. An additional benefit was having a second junior surgeon on a second control station who could monitor, comment on, and learn from the case. While not included in this series, the robot (in Denver, CO) was also accessed and controlled from New Zealand and Vietnam, miles away, proving that this technology could be used worldwide, although there was a time delay noted especially when trying to maneuver the robot. However, communication and movement of the robot when done within the continental United States was almost instantaneous.

The greatest benefits seemed to be in setting up the surgery (positioning, trocar placement, etc.), identifying the pathology, and discussing how best to approach the repair (Fig. 3). In general, the mentor felt the visualization of the operative field was good to excellent and allowed for mentoring on a level that was equivalent to that had he been in the room. It should be noted that extra care needed to be taken in maneuvering the robot because of the sterile surgical field and the numerous personnel and equipment in the room. This issue is probably the greatest drawback of having the robot in the operating room. A ceiling-mounted robot on some sort of track might be the best way to alleviate this issue.

There were two areas where the operative team and the mentor felt there could be improvement. The first would be if the endoscopic image was transmitted directly from the camera to the remote control station rather than through the camera of the robot looking at one of the in-room monitors. An overhead room camera tied in the same way, to view the patient, would also be beneficial. This would assuredly improve the quality of the image that the remote site received. Other digital images such as X-rays could also be transmitted by direct feeds, and in fact this is routinely done in institutions where the RP-7 is used to round on patients. The second would be to have the surgeon wear a headset with direct audio communication to the mentor as the in-room noise could somewhat interfere with the mentor's voice.

The cost of the current technology is not insignificant and therefore make it somewhat less practical. However, the advantage of using the RP-7 in its current form is that it can then be used in other areas of the hospital. A dedicated version of the RP-7 adapted to the operating room environment and incorporated into the endoscopic suite might make the unit more cost-effective.

Overall, the entire surgical team felt that the value of the interaction overcame any of the inconvenience of having the robot in the operating suite, and this technology should be pursued to make it more OR-friendly.

Disclosure Statement

No competing financial interests exist.

References

1. Wolfe BM, Szabo Z, Moran ME, Chan P, Hunter JG. Training for minimally invasive surgery: need for surgical skills. *Surg Endosc* 1993;7:93-95.
2. Moore RG, Adams JB, Partin AW, Docimo SG, Kavoussi LR. Telementoring of laparoscopic procedures: initial clinical experience. *Surg Endosc* 1996;16:1389-1402.
3. Emken JL, Mcdougall EM, Clayman RV. Training and assessment of laparoscopic skills. *JSL* 2004;8:195-199.
4. Ellison LM, Nguyen M, Fabrizio MD, Soh A, Permpongkosol S, Kavoussi L. Postoperative robotic telerounding: a multi-center randomized assessment of patient outcomes and satisfaction. *Arch Surg* 2007;142:1177-1181.

Address reprint requests to:
Steven S. Rothenberg, MD
 1601 E. 19th Ave., Suite 5500
 Denver, Colorado 80218

E-mail: steverberg@aol.com